

# Safety in the neonatal and infant transport system: report on three cases with evidence-based comments on safety during transportation

STEFAN GROSEK (✉)  
University Medical Center Ljubljana  
Surgical Service  
Department of Pediatric Surgery  
and Intensive Therapy  
Medical Faculty, University of Ljubljana  
Bohoriceva 20, 1525 Ljubljana, Slovenia  
GSM ++ 386 (0)41 684 206  
Phone: 386 (0)1 522 48 29  
Phone: ++ 386 (0)1 522 33 49  
Fax: ++ 386 (0)1 522 11 09  
E-mail: stefan.grosek@mf.uni-lj.si  
E-mail: stefan.grosek@kclj.si  
Web page: www.kclj.si

STEFAN GROSEK

## ABSTRACT

*Infant transport has been carried out in Slovenia since 1976. Applying the principles of safe transport was essential to avoid unexpected exposure of critically ill infants to unnecessary and adverse events. Besides organizational and technical prerequisites for safe transportation, evidence-based clinical knowledge and practical competence are of utmost importance. Furthermore, the ongoing possibility of consulting other colleagues during transportation, choose the optimal form of retrieval of very sick infants, is sometimes needed and preferred. Three different cases are presented here where skilled medical teams decided how to transport critically ill infants, and at what risks and costs. All three transports were successfully completed with good outcomes despite difficult clinical conditions prior to and during retrieval.*

**Key words:** safety, neonatal transport, pneumothorax, prostaglandin infusion, extracorporeal membrane oxygenation

## Introduction

The safe neonatal transport system in Slovenia was started in 1976, two years after the new and modern Neonatal and Pediatric Intensive Care Unit at the University Medical Centre Ljubljana was opened in 1974. (1,2) Those were the days when the regionalization of medical care in specialized tertiary centres together with the need for a specialized retrieval neonatal transport system evolved in Europe, including in Slovenia. (3,4) A dedicated team, consisting of a pediatric intensivist and a registered nurse, together with an ambulance or helicopter crew, took responsibility for the safe transfer of critically ill infants. (2) The primary roles of a referral medical team are to recognize a critically ill infant, to take care of him/her until a transport team arrives and to hand-over

safely and correctly the infant to the transport team. A secondary role of the referral team is how the transport team should make a proper and on-site decision for the safe retrieval of the critically ill infant. A focus on transport safety in three different clinical situations with evidence based comments will be presented in the paper below.

## Case report 1 Can we safely accept expectant management of pneumothorax in the case of a critically ill infant who has to be transported by helicopter or ambulance to the intensive care unit?

A one day old infant, body weight 2460 grams, length 47 cm, head circumference 32 cm, Apgar 10/10 at 1 and 5 minutes consecutively, of 37 weeks gestation, delivered vaginally, developed respiratory distress syndrome (RDS) which necessitated orotracheal intubation and artificial hand bagging

ventilation with pure oxygen. A transport team was called to transfer him to the Neonatal and Pediatric Intensive Care Unit (ICU), University Medical Centre Ljubljana. A referral doctor reported that after intubation and artificial ventilation, the oxygen saturation of the infant improved and was well above 90%. His circulatory status was stable, too. A neonatal transport team was assembled within 45 minutes after the first call was made and needed a further 1 hour and 15 minutes to reach the regional maternity hospital by ambulance. On arrival, the clinical condition of the baby at first sight seemed stable, blood gases were appropriate, he was pink and warm. A clinical diagnosis of RDS and hyposurfactosis was suspected. A chest radiograph confirmed this. A brief comment by the referral doctor was that the lungs were less compliant and did not change during the last two hours; the compliance of the lungs neither improved nor decreased. Prior to transportation, a chest radiograph showed

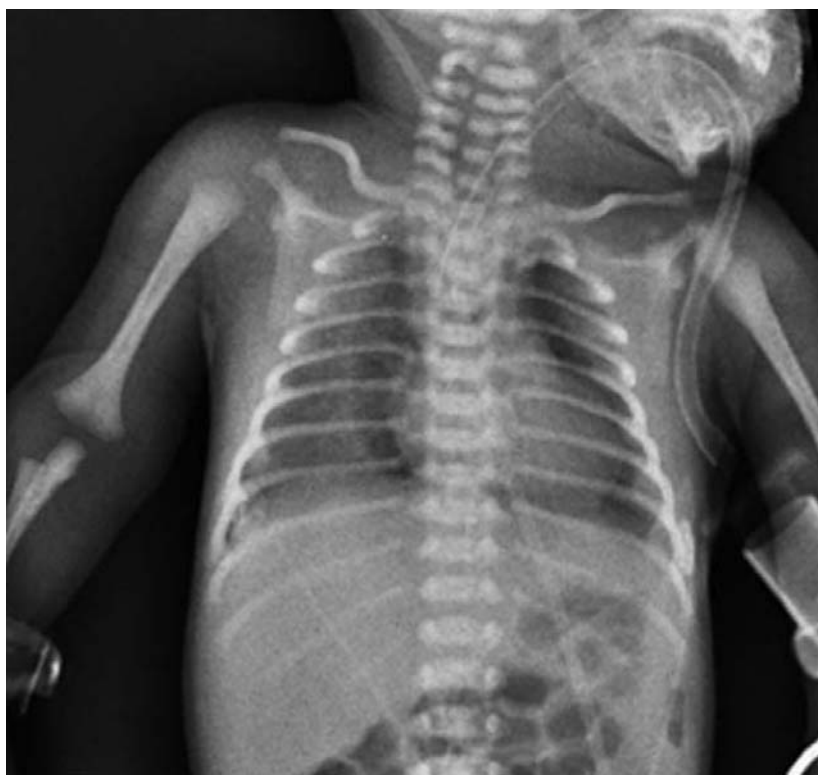a small pneumothorax on the right and left side of the lungs (figures 1,2).

The transport doctor's dilemma before retrieval was whether to insert a thoracic tube to remove the air from the pleural cavity or to manage it expectantly, i.e., to delay the procedure until arriving at the ICU and performing it, if still needed. The infant was stable, with good capillary refilling, therefore no cardiovascular compromise was evident, peripheral skin saturation was well above 95% on 80% of oxygen and hyaline membrane disease certainly was a predominant cause of his problems. Our present policy is to wait with artificial surfactant instillation until the patient is transferred to a safe place, i.e. to the neonatal and pediatric ICU, where a dedicated team of intensivists are able to solve the clinical problem in a safe environment.

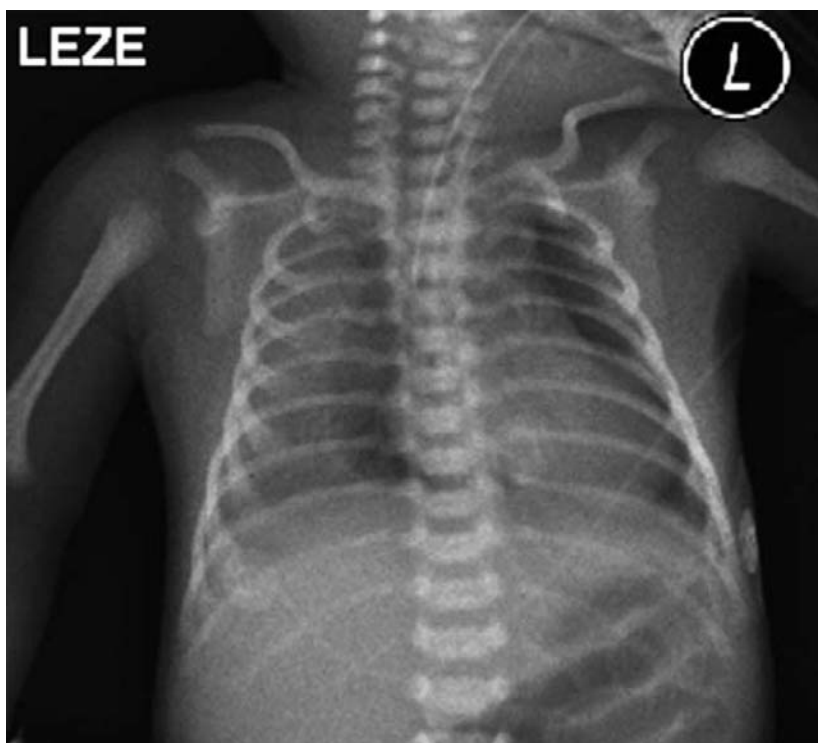Transportation to the neonatal ICU lasted 1 hour and 15 minutes and was accomplished without problems either during or immediately after transportation. After checking the vital signs and repeating the chest radiograph (figure 3), which did not show any deterioration regarding the air-leak, a decision on how to further approach treatment in the ICU, besides oxygen and respiratory support with artificial ventilation, was made. While artificial surfactant was warmed up at room temperature, a needle puncture on the right side of the chest showed a positive sign of air bubbles in the syringe. Therefore, a chest tube was placed in the right pleural cavity (figure 4). After instilling artificial surfactant, there was further improvement in compliance of the lungs, decreasing the need for Fraction of Inspired Oxygen ( $FiO_2$ ) (figure 5). The small pneumothorax on the left side was resolved with no invasive intervention needed. Eventually the right chest tube was removed on day 4, the tracheal tube on day 7 and the patient was discharged back to the regional maternity hospital on day 8.

### Discussion of Case 1

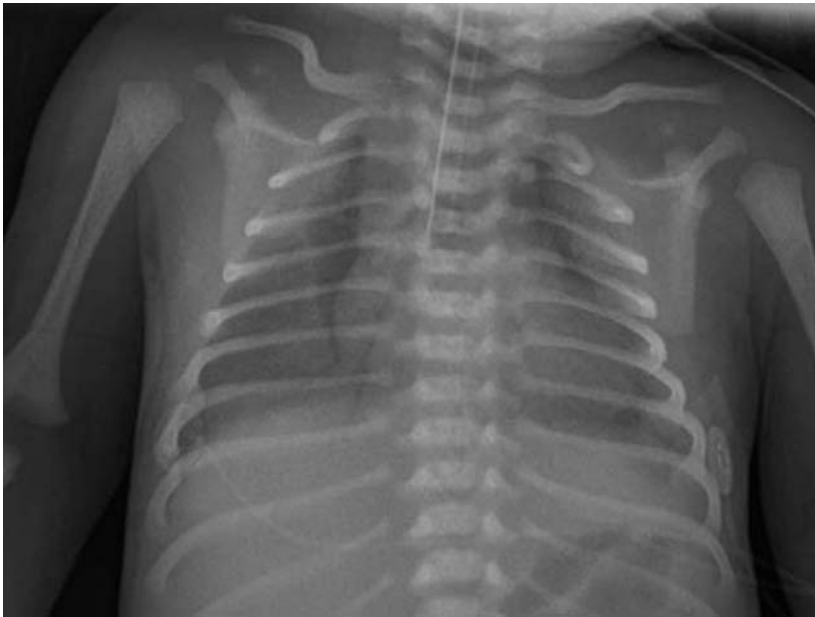
A lively discussion arose the next day during the bedside morning ward round regarding the necessity for pre- instead of post-transport placement



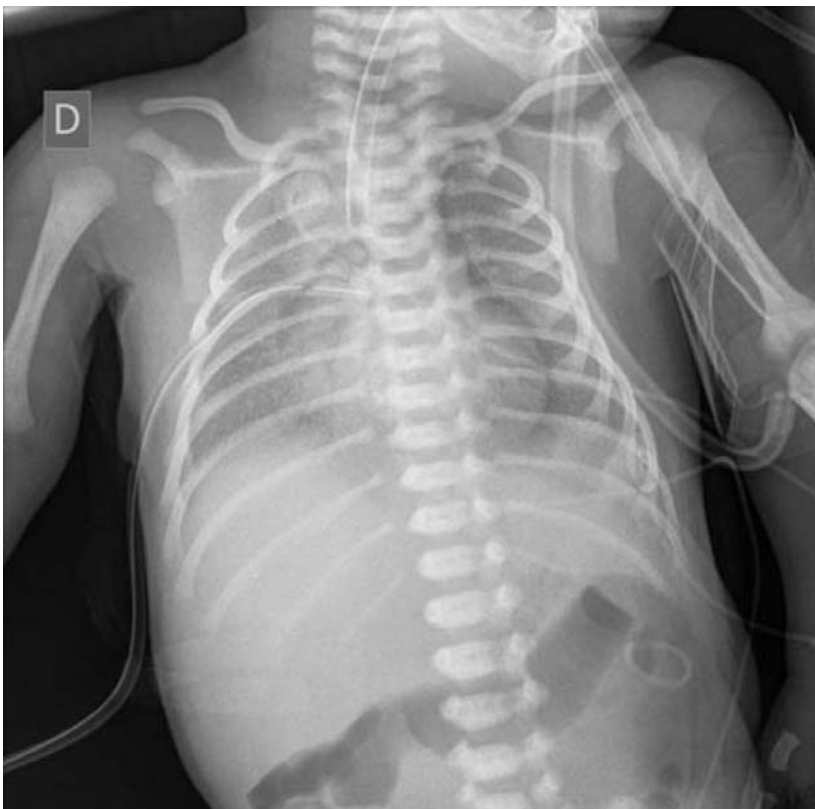**Figure 1. A chest x-ray with evident signs of hyaline membrane disease and pneumothorax on the right and left sides of the chest.**



**Figure 2. A chest x-ray of the same infant showing no deterioration 40 minutes later, before we left the regional maternity hospital.**



**Figure 3. Chest x-ray of the same infant 15 minutes after arrival to the intensive care unit, University Medical Centre Ljubljana. No differences in pneumothoraxes seen in comparison with pictures 1 and 2.**



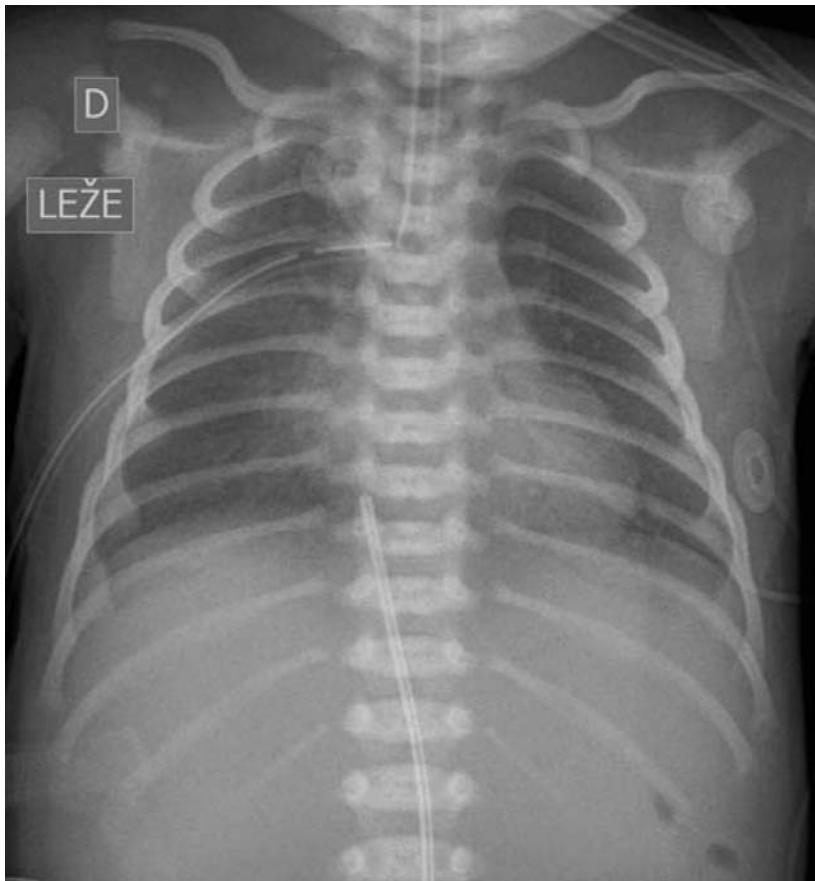**Figure 4. Chest x-ray after insertion of a chest tube in the right hemithorax.**

of the chest tube. This question was important for the transport intensivist, because it is well known that firstly,

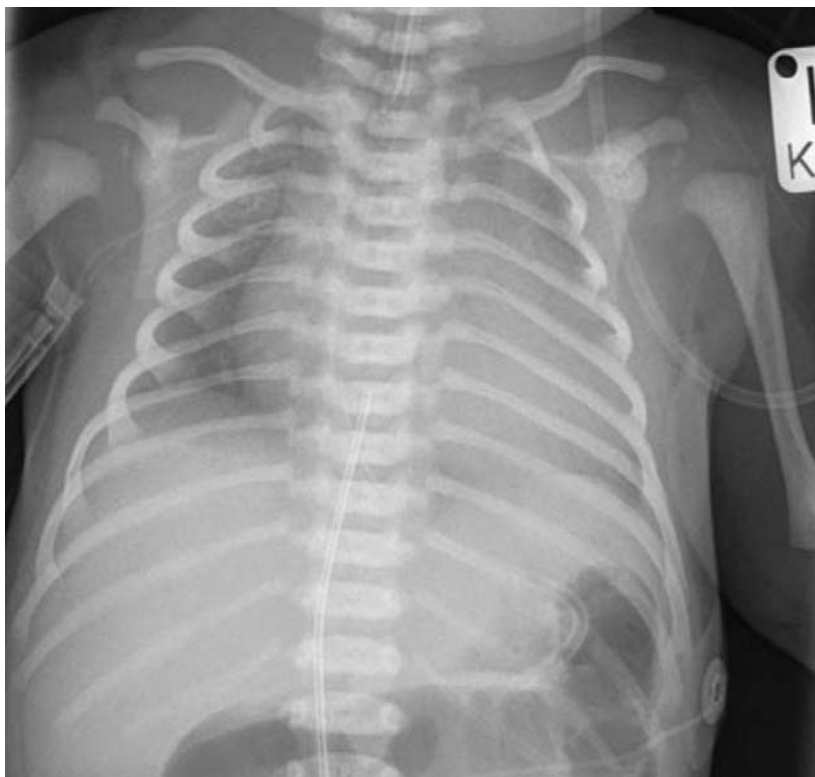pneumothorax is more frequent in the neonatal period and that it occurs more frequently in transported infants than

in inborn-infants. (5) However, chest tube insertion may cause lung injury, (6) phrenic nerve paralysis and many others adverse effects. What would happen if the air-leak further deteriorated during transportation? Would it be wise to decide for expectancy, i.e., to wait instead of adopting an active approach with needle aspiration and chest tube insertion? An expectant decision relies on the following point of view: such an infant would never be transported without a chest tube if he had to be transported by helicopter or if he had severe cardiorespiratory problems deteriorating from the first doctor's call from the maternity hospital. A transport doctor has to be aware of accelerations and decelerations, influences of decreased atmospheric pressure in unpressurized helicopters at higher altitudes and possible increase of air-leak in the chest cavity. Furthermore, insertion of a chest tube is not possible when the helicopter is in the air. If problems related to air-leak arise in a car ambulance the transport team can just stop the ambulance on the hard shoulder of the motorway and perform such a procedure. Moreover, there were no problems with increasing altitude and decreasing atmospheric pressure and no acceleration or deceleration as can be expected in helicopters. However, car ambulance transfer may be problematic for the transport of a critically ill infant in regions on the Earth's surface high above sea level, i.e. over 2400 meters above sea level, when the car ambulance has to pass high altitude and then descend to reach the hospital which is only 300 to 500 meters above sea level.

An interesting retrospective study about expectant management of pneumothorax in ventilated infants was recently published by Ita Litmanovitz et al. which confirmed that in some circumstances no chest tube insertion is a must. (7) She evaluated 136 infants with pneumothorax between 1992 and 2005 who were on mechanical ventilation. One quarter (26%) were not initially treated with a chest tube. Of those initially untreated with a chest tube, 14 were treated with needle aspiration and 21 with expectant treatment. Among these two groups,



**Figure 5. Chest x-ray after instillation of artificial surfactant.**

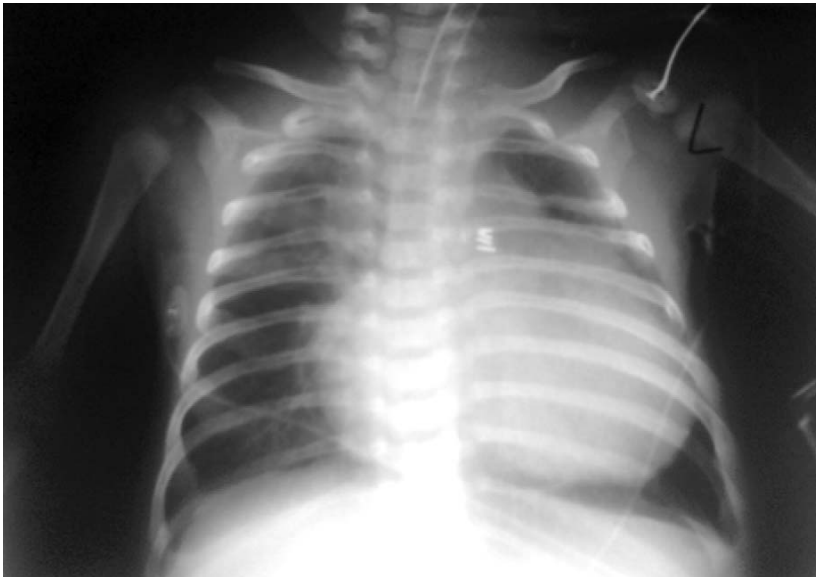

**Figure 6. Chest x-ray of the infant on prostaglandin E1 infusion after admission to the intensive care unit.**

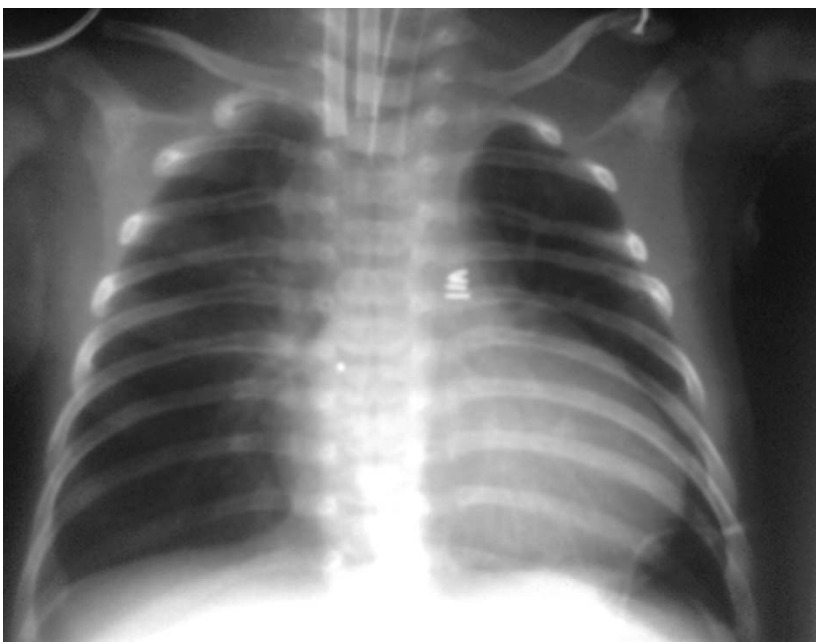
of those who were treated with needle aspiration, 43% finally needed chest tube insertion, while only 10% in the expectant group. They concluded that a select group of infants on mechanical ventilation can be treated expectantly without initial chest tube placement. (7) The marked current practice variation exists among pulmonologists and thoracic surgeons treating spontaneous pneumothorax and bronchopleural fistula. This study showed that more than 50% of clinicians used a chest tube in mechanically ventilated acute respiratory distress syndrome, acute respiratory distress syndrome (ARDS) related tension pneumothorax in adults, while in small spontaneous pneumothorax were treated expectantly. (8) In blunt occult pneumothorax, Barrios et al. found that management without tube thoracotomy was adopted in 59 cases and was successful in 51 (86%). Observation was successful in 16 out of 20 occult pneumothoraxes (80%) exposed to positive pressure ventilation within 72 hours of admission. (9)

**Case report 2**  
**Is expectant intubation and mechanical ventilation of an infant with a congenital heart defect that was started on a prostaglandin infusion just before transfer to the ICU safe?**

This was an eight hour old female infant, delivered after the second uneventful pregnancy of her 28-year old mother, birth weight 3560 grams, length 51 cm, head circumference 34 cm, 38 weeks of gestation, Apgar 9 and 10 at 1 and 5 minutes consecutively, who developed cyanosis and was suspected to have duct dependent congenital heart disease (CHD). A phone call from the doctor from the referral hospital informed the pediatric intensivists in the admitting hospital, that the hyperoxic test with 100% oxygen was positive for cyanotic CHD. A loud holosystolic murmur with accentuated third tone on auscultation of the heart was heard. Preductal oxygen saturation did not reach higher than 92%, and the baby had visible central cyanosis. Otherwise she looked well with a normal



**Figure 7. Chest x-ray of the infant who needed extra corporal membrane oxygenation support before transport.**



**Figure 8. Chest x-ray of the infant after cannulation and extra corporal membrane oxygenation started.**

breathing pattern. Her chest radiograph showed an enlarged heart and good transparency of the lungs (figure 6). Safe transportation with a pediatric intensivists and registered nurse was requested. Transportation by helicopter was organized to transfer the cyanotic baby as soon as possible to the Pediatric and Neonatal ICU. The referral doctor was encouraged by the intensivists to start therapy with Prostaglandin E1, PgE1,

if available in their hospital, and also to be aware of the possible side effects of PgE1, especially of apnoeic spells. On the arrival of the transport team, the baby was lying on the resuscitation bed; she was eupnoic, cyanotic despite oxygen through nasal prongs. No PgE1 had been received so far, because they did not have PgE1 stored in their pharmacy. As ductus dependent CHD was very likely, the transport doctor decided to

start with PgE1 infusion and transferred the baby without intubation or artificial ventilation despite helicopter transportation. Her vital signs were stable after the infusion of PgE1 was started. The transport doctor decided to transfer the baby to ICU in a transport incubator on spontaneous breathing with optimal oxygen saturation between 80 and 90% with oxygen delivery through nasal prongs. The helicopter transfer went smoothly. As the helicopter took off an apnoeic spell with oxygen desaturation occurred. Tactile stimulation did not improve her condition and the necessity for intubation forced the helicopter to land on the helipad. The pilot switched off the engine to stop the helicopter vibrations and to allow doctors to manage intubation and artificial ventilation. After the intubation and connection of the baby to the transport ventilator no further problems occurred during and after landing at the hospital.

After echocardiography was done in the ICU by an experienced pediatric cardiologist, a dysplastic tricuspid valve with severe regurgitation and pressure gradient of at least 35 mmHg was found, as well as an atrial septal defect (ASD) secundum with right to left shunt. Mild dilation of the right ventricle was also observed. Nitric oxide was added to the therapy together with on-going PgE1 infusion according to recommendations for this type of CHD. (10) In the following days, she was gradually weaned from PgE1 and nitric oxide, and was extubated and transferred to the pediatric cardiology ward on day 8.

## Discussion of Case 2

What is the occurrence of apnoeic spells after PgE1 infusion and should the infant be intubated when helicopter transportation is arranged? According to the data, apnoeic spells occur in more than 10% of infants on PgE1 infusion and is higher if a dose higher than 15 nanogram/kg/minute is used in the first hour in neonates with a body weight of less than 2 kg. (11) Recent studies have shown that transport of nonintubated infants who are on PgE1 infusion is safe and those who are

electively intubated before transportation undergo more complications than those who are not. (12-15) According to the latest recommendation of the Slovenian task group for the safe transportation of infants with ductus dependent CHD on PgE1 infusion, relative indications for intubation and mechanical ventilation are: diseases which require intubation and artificial ventilation, severe hypoxemia, hypotension, metabolic acidosis or cardiorespiratory failure, apnoea after initiation of PgE1 infusion which lasts despite tactile stimulation or short mask ventilation, some special modes of transportation like helicopter, long road transportation and bad weather reports. They suggested that at least 30 minutes after the initiation of PgE1 infusion the baby should be monitored for side effects and apnoea, and only afterwards should a nonintubated and nonventilated infant begin with transfer back to the admitting hospital. (15) This case is interesting because it shows that if the doctor had followed the recommendations for transportation of infants on PgE1 infusion the likelihood of apnoea during take-off would have diminished and it would have probably occurred when the helicopter was still on the ground.

### **Case report 3 How safe is expectant extracorporeal membrane oxygenation (ECMO) treatment in infants who are ECMO candidates?**

This case is a one month and 25 day old infant girl who had a prenatally confirmed congenital heart defect. She was born vaginally, weighing 3080g and 50 cm long. When she was 1 month old, a surgical correction of the hypoplastic aortic arch and coarctation of aorta, ligation of patent ductus arteriosus (PDA) and bandage of pulmonary artery due to ventricular septal defect (VSD) and ASD was performed. Her postoperative course was uneventful and she was transferred to the ward on day eight with edemid 2 mg and aldactone 3 mg administered once per day. She was on a milk formula without fat, Basic F formula with medium-

chain triglycerides (MCTs) oil given orally 1-1.5 ml/ with each meal. Nineteen days after the operation she was discharged home on the same antidiuretic therapy as mentioned above in good clinical condition and was stable. One month after the operation she was examined during her regular appointment by a pediatric cardiovascular surgeon. He found her in excellent condition and felt no need for further antidiuretic therapy or restriction of fluids.

Twelve days later she was admitted by an emergency doctor to the pediatric intensive care unit of the University Medical Centre Maribor because of respiratory distress, feeding difficulties and hypothermia. Her oxygen saturation on air was 80%, she was tachycardic with 172 beats/minute, respiratory rate 52/minute and the noninvasively measured blood pressure in the right leg was 83/59 mmHg. A grossly enlarged heart was seen on the chest radiograph (figure 7). Echocardiography revealed an ejection fraction of only 26%. She was put on inotropes and later on vasopressors (norepinephrine, dobutamine and dopamine) and because respiratory failure ensued, she was tracheally intubated and placed on mechanical ventilation. Afterward she developed severe sudden bradycardia and required complete resuscitation with epinephrine given three times. A transport team from the University Medical Centre Ljubljana was asked to transfer the girl by helicopter most probably for extracorporeal membrane oxygenation, ECMO, to support her failed myocardium, of unknown cause. Prior to transfer her C-reactive protein was 4 mg/ml, procalcitonin 0,042 ng/ml, leukocytes  $17,2 \times 10^9/L$ , erythrocytes  $3,7 \times 10^9/L$ , hemoglobin 106 g/L and hematocrit 0,33, urea 2,9 mmol/L, creatinine 30 micromol/L, pH 7.32, base excess, BE -9.7,  $pCO_2$  3,75 kPa.

On admission she was sedated and mechanically ventilated with  $FiO_2$  1.0; her oxygen saturation was 90%. Her pupils were reactive to light. She was supported with norepinephrine, dopamine and dobutamine, her blood pressure was 66/48 mm Hg, and she had a heart rate of 187 beats/minute. Her skin was cold, dry and pale. Both lungs were symmetrically and

equally ventilated with normal breath sounds. A loud, systolic murmur was heard in the whole precordium. Capillary refilling time was prolonged with weak femoral pulses. The abdomen was soft with audible intense peristalsis.

Laboratory tests on admission were as follows: C-reactive protein 14 mg/ml, leukocytes  $14,0 \times 10^9/L$ , erythrocytes  $3,17 \times 10^9/L$ , hemoglobin 89 g/L, hematocrit 0,27, platelets  $316 \times 10^9/L$ , glucose 8.4 mmol/L, K 4.9 mmol/L, Na 148 mmol/L, Cl 102 mmol/L, Ca 1.64 mmol/L, P 2.81 mmol/L, Mg 1.02 mmol/L, urea 7,2 mmol/L, creatinine 86  $\mu$ mol/L, protein 40 g/L, albumin 25 g/L, troponin 1 ng/ml, urea 21.2 mmol/L, lactate 19.4 mmol/L. Blood gases: pH 7.56,  $pCO_2$  2.6,  $pO_2$  12.0,  $HCO_3$  16.9, cel.  $CO_2$  17.5, BE -3.9.

Her cardiocirculatory condition deteriorated rapidly, so she was put on venoarterial extracorporeal membrane oxygenation support (V-A ECMO) for seven days (figure 8). During and just before ECMO connection she was resuscitated five times. Her cardiocirculatory condition under ECMO support improved. She developed acute renal failure and was on peritoneal dialysis for twelve days. Because of resuscitation, she went into induced hypothermia for five days, with a core temperature between 33 and 34  $^{\circ}C$ . Neurologically, she fully recovered during her stay in our ICU.

On day 20 she was transferred to the ward but 10 hours later was readmitted to the ICU because of sudden deterioration. This time recoarctation of the aorta was confirmed, catheterization with balloon dilation of the narrowed aorta transiently relieved her symptoms, finally she was re-operated upon and a plastic aortic repair with pericardial patch was inserted.

### **Discussion of Case 3**

This case is interesting because some infants might need ECMO support while waiting for transfer to a tertiary Neonatal and Pediatric ICU with available ECMO support and the issue is whether or not to transport such critically ill infants. In centres with developed, so called mobile ECMO, they simply reach a baby, connect him/her

to the ECMO and safely transport him/her back to the ICU. Not all units have mobile ECMO teams available and they have to make decisions based on their own experience of whether such an infant is transportable or not. It should firstly be noted that in experienced teams, transported and non-transported ECMO patients have the same chance of survival. (16) Even patients with cardiac dysfunction can be safely transported by ECMO teams. (17) Wilson BJ et al. warn of risk-laden mortality that should not replace early referral to an ECMO centre despite acceptable survival. (18) Mobile ECMO teams were able to modify their criteria for selecting infants for long-distance transfer which were more rigorous. (19) Because mobile ECMO is very expensive, early referral of critically

ill infants before all modern technical and medical therapies are exhausted is encouraged in our unit. (20,21) In our case, the decision to transport the critically ill infant was not questionable, at any moment, due to cardiac failure. It also showed that short, even repeated, resuscitation had no impact on the neurological outcome of the girl. Even renal failure was not prognostic in her case, although some authors have found that renal failure is usually a fatal complication of ECMO. (19) Perreault T., in his editorial, challenges clinicians about the use of ECMO and invites them to consider all therapies: high frequency ventilation, nitric oxide and ECMO, in each centre, in order to ensure the safety of the patient, not only in terms of survival, but also of outcome. (22) Our experience, based

on 20-years of ECMO use, support the continuation of the ECMO program, but earlier referral is better than later and lower criteria certainly are better for the outcome than higher. (20)

## Conclusions

Regionalized tertiary intensive care units together with dedicated neonatal transport teams improve the outcomes of critically ill infants. Transport teams will always be faced with some unexpected events which do or do not become adverse. Our well-trained transport team, which has worked together for more than 30 years, incorporates strategies for risk reduction in its everyday work. However, individual decisions have been made based on individual perceptions of the clinical situation and we have hereby presented three such cases.

---

## ACKNOWLEDGMENTS

The author thanks the medical staff at the Department of Pediatric Surgery and Intensive Care, University Medical Centre Ljubljana, particularly the nurses and doctors who participated in the transport and further treatment of neonates.

---

## REFERENCES

1. Grosek S, Mlakar G, Vidmar I, Ihan A, Primožič J. Heart rate and leukocytes after air and ground transportation in artificially ventilated neonates: a prospective observational study. *Intensive Care Med* 2009;5(1):161-5.
2. Grosek S. Secondary neonatal and infant transport. In: Primožič J, Grosek S, eds. *XIth Educational Seminar: Critically ill and injured child: recognition, treatment and transport*. Ljubljana: Klinični oddelek za otroško kirurgijo in intenzivno terapijo, Kirurška klinika, Univerzitetni Klinični center. 2008. p. 33-7.
3. Fenton AC, Leslie A, Skeoch CH. Optimising neonatal transfer. *Arch Dis Child Fetal Neonatal Ed* 2004; 89(3):F215-9.
4. Ratnavel N. Safety and governance issues for neonatal transport services. *Early Hum Dev* 2009; 85(8):483-6.
5. Trevisanuto D, Doglioni N, Ferrarese P, Vedovato S, Cosmi E, Zanardo V. Neonatal pneumothorax: comparison between neonatal transfers and inborn infants. *J Perinat Med* 2005; 33(5):449-54.
6. Strife JL, Smith P, Dunbar JS, Steven JM. Chest tube perforation of the lung in premature infants: radiographic recognition. *AJR Am J Roentgenol* 1983; 141(1):73-5.
7. Litmanovitz I, Carlo WA. Expectant management of pneumothorax in ventilated neonates. *Pediatrics* 2008;122(5):e975-9. Epub 2008 Oct 13.
8. Baumann MH, Strange C. The clinician's perspective on pneumothorax management. *Chest* 1997; 112(3):822-8.
9. Barrios C, Tran T, Malinoski D, Lekawa M, Dolich M, Lush S, et al. Successful management of occult pneumothorax without tube thoracostomy despite positive pressure ventilation. *Am Surg* 2008;74(10):958-61.
10. Jaquiss RD, Imamura M. Management of Ebstein's anomaly and pure tricuspid insufficiency in the neonate. *Semin Thorac Cardiovasc Surg* 2007;19(3):258-63.
11. Browning Carmo KA, Barr P, West M, Hopper NW, White JP, Badawi N. Transporting newborn infants with suspected duct dependent congenital heart disease on low-dose prostaglandin E1 without routine mechanical ventilation. *Arch Dis Child Fetal Neonatal Ed* 2007;92:F117-9.
12. Meckler GD, Lowe C. To intubate or not to intubate? Transporting infants on prostaglandin E1. *Pediatrics* 2009;123:e25-30.
13. Ferrarese P, Marra A, Doglioni N, Zanardo V, Trevisanuto D. Routine mechanical ventilation for transferred neonates with duct-dependent congenital heart disease. *Arch Dis Child Fetal Neonatal Ed* 2007;92:F422.
14. Bouchut JC, Teyssedre S. Lessons from transporting newborn infants with known or suspected congenital heart disease. *Paediatr Anaesth* 2008; 18:679-81.
15. Grošelj Grenc M, Pavčnik Arrol M, Kalan G, Podnar T, Vidmar I. Treatment of neonates with congenital heart defects, who need therapy with Prostaglandin E. *Zdrav Vestnik* 2012;81: 91-8.
16. Clement KC, Fiser RT, Fiser WP, Chipman CW, Taylor BJ, Heullitt MJ, et al. Single-institution experience with interhospital extracorporeal membrane oxygenation transport: A descriptive study. *Pediatr Crit Care Med* 2010; 11(4):509-13.
17. Cabrera AG, Prophan P, Cleves MA, Fiser RT, Schmitz M, Fontenot E, et al. Interhospital transport of children requiring extracorporeal membrane oxygenation support for cardiac dysfunction. *Congenit Heart Dis* 2011;6(3):202-8. doi: 10.1111/j.1747-0803.2011.00506.x.
18. Wilson BJ Jr, Heiman HS, Butler TJ, Negaard KA, DiGeronimo R. A 16-year neonatal/pediatric extracorporeal membrane oxygenation transport experience. *Pediatrics* 2002;109(2):189-93.
19. Weber TR, Connors RH, Tracy F, Jr, Bailey PV, Stephens C, Keenan W. Prognostic Determinants in Extracorporeal Membrane Oxygenation for Respiratory Failure in Newborns. *Ann Thorac Surg* 1990;50:720-3.
20. Vidmar I, Primožič J, Kalan G, Grosek G. Extracorporeal membranous oxygenation (ECMO) in neonates and children experiences of a multidisciplinary paediatric intensive care unit. *Signa Vitae* 2008;3 Suppl 1:S17-21.
21. Primožič J, Kalan G, Grosek S, Vidmar I, Lazar I, Kosin M, et al. Extracorporeal membrane oxygenation-12 years experiences. *Zdrav Vestnik* 2006;75:61-70.
22. Perreault T. ECMO or no ECMO: Do no harm. *An Esp Pediatr* 2002;57(1):1-4.